

# CAP TODAY

PATHOLOGY ♦ LABORATORY MEDICINE ♦ LABORATORY MANAGEMENT

## Coexisting germline mutations in *APC* and *BRCA2* in a patient with colon cancer

CAPTODAY and the Association for Molecular Pathology have teamed up to bring molecular case reports to CAP TODAY readers. AMP members write the reports using clinical cases from their own practices that show molecular testing's important role in diagnosis, prognosis, and treatment. Case report No. 8, which begins here, comes from Danbury Hospital, Western Connecticut Health Network. If you would like to submit a case report, please send email to the AMP at [amp@amp.org](mailto:amp@amp.org). For more information about the AMP, visit [www.amp.org](http://www.amp.org).



**Tsetan Dolkar, MD**  
**Jennifer Zikria, MD**  
**Stuart Bussell, MD**

**Shannon Morrill-Cornelius, MS, CGC Rina Siddiqui, MD**

Tumor suppressor genes direct the production of proteins that regulate cell division. Mutations in these genes result in uncontrolled cell growth and may contribute to the development of a cancer. Adenomatous polyposis coli (*APC*) and breast cancer 2 (*BRCA2*) are two such genes.

Pathogenic mutations in the *APC* gene cause familial adenomatous polyposis (FAP), an autosomal dominant inherited disorder, characterized by early-onset colorectal cancer. People with classic FAP develop colonic polyps in their teenage years that eventually undergo malignant transformation. The average age for presentation with colorectal cancer is 39 years. Attenuated FAP (AFAP) is a phenotypically distinct entity, typically presenting with fewer than 100 adenomas. The average age for presentation with colorectal cancer for AFAP is 55 years.<sup>1</sup>

Heterozygous mutations of the *BRCA2* gene can lead to an increased risk of cancers involving the breast in both male and female, ovary, prostate, pancreas, fallopian tube, and skin (melanoma).

**Case presentation:** A 44-year-old Caucasian male of Hungarian, Czechoslovakian, and Irish descent with no

significant past medical history presented with abdominal pain, distension, nausea, projectile vomiting, and loose stool for a week. He denied fever or chills and had no recent travel or trauma.

He also reported unintentional weight loss of 90 pounds in the past two years, with 20 pounds lost in the prior two months. Computed tomography scan of the abdomen and pelvis showed a 3.7-cm "apple core" lesion of the rectosigmoid colon causing large and small bowel obstruction without distant metastasis.

He underwent sigmoid colectomy with end colostomy and ileal colostomy that found a pT4a pN2a M1 colonic adenocarcinoma with 15 additional colon polyps. The tumor was microsatellite stable by immunohistochemistry. Formalin-fixed, paraffin-embedded tumor tissue sent for next-generation sequencing resulted in the diagnosis of a pathogenic somatic *KRAS* mutation (G12A). Postoperative CEA level was 55 ng/mL (normal 0.0–4.3), which prompted a PET scan that found focal uptake in the right lobe of liver demonstrating SUV uptake 10. The liver lesion was also seen on MRI and underwent biopsy, confirming metastatic colonic adenocarcinoma.

The patient was evaluated by a hepatobiliary surgeon and it was recommended that he proceed with adjuvant rather than neoadjuvant liver resection. He was treated with FOLFOX (FOL—folinic acid [leucovorin], F—flourouracil [5-FU], and OX—oxaliplatin [Eloxatin]) and bevacizumab (Avastin) for six cycles. At the completion of chemotherapy, MRI and CT scan showed no residual lesions and a normal CEA of 1.1 ng/mL.

As multiple colonic polyps were seen on colonoscopy, he was referred for genetic counseling. Family history was remarkable for pancreatic cancer in his father at age 50 and colon cancer in his mother and maternal cousin once removed at ages 74 and 54, respectively. The patient is estranged from the paternal side of his family, so that history was unavailable (see pedigree, page 2).

After counseling, he decided to pursue genetic testing. Peripheral blood in EDTA was sent to Ambry Genetics. A panel of 14 genes associated with hereditary colon cancer was tested first by next-generation sequencing and confirmed by Sanger sequencing. The panel included *APC*, *BMPR1A*, *CDH1*, *CHECK2*, *EPCAM*, *MLH1*, *MSH2*, *MSH6*, *MUTYH*, *PMS2*, *PTEN*, *SMAD4*, *STK11*, and *TP53*. He was diagnosed with a pathogenic mutation in the *APC* gene due to a C to T substitution at nucleotide position 1213 in exon 9. The mutation resulted in a premature stop codon instead of the amino acid, arginine (p.R405X) (Figs. 1 and 2).

The patient had consented to his DNA being used anonymously for research purposes. The DNA was used to validate *BRCA1* and *BRCA2* testing for this laboratory. Months after his AFAP diagnosis was made, the laboratory inadvertently unmasked his *BRCA1* and *BRCA2* results, and his genetic counselor was contacted and asked if the patient would be interested in having those results. The patient consented, blood was drawn for clinical confirmation of the research result, and the patient was informed that he has the deleterious c.8297delC alteration in the *BRCA2* gene (Figs. 3 and 4).

He ultimately underwent colostomy reversal. Unfortunately, seven months after colostomy reversal his CEA levels began increasing, rising to 38 ng/mL, and CT scans found a local recurrence at the anastomosis site and three liver lesions. He then underwent complete proctectomy because of the AFAP mutation and excision

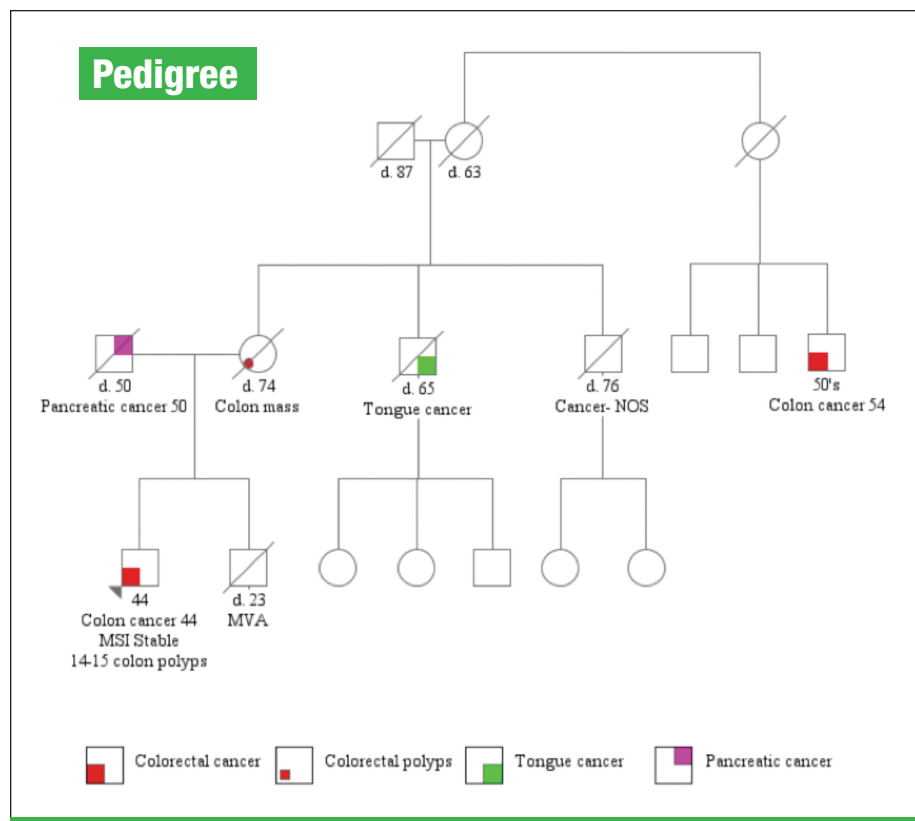
of the liver implants. He is currently receiving adjuvant chemotherapy with 5-FU and Avastin. Because of the AFAP mutation he is being followed by routine surveillance with upper endoscopy, and thyroid examination. For his *BRCA2* mutation, he requires surveillance with annual PSA screening, mammography, and ophthalmologic evaluation.

**Discussion:** Colorectal carcinoma is one of the leading causes of cancer death in men and women in the United States. While significant progress has been made in the treatment of metastatic colorectal carcinoma, one of the major challenges is resistance to chemotherapy treatment. *KRAS* is an oncogene that functions downstream to membrane-bound receptors such as EGFR. Mutations in *KRAS* result in a constitutively activated protein leading to unregulated proliferation, impaired differentiation, and resistance to EGFR inhibitors.<sup>2</sup> The G12A point mutation activates *KRAS* and is associated with resistance to EGFR tyrosine kinase inhibitors (erlotinib, gefitinib) and monoclonal antibodies (cetuximab, panitumumab).<sup>3-5</sup>

Friedl, et al., noted that alternatively spliced sequence of exon 9 and mutations in 5' to codon 168 and 3' to codon 1580 were associated with AFAP phenotype.<sup>6</sup> A review of the literature revealed one case report in German that described the same mutation our patient had in an asymptomatic 59-year-old female with multiple tubular and tubulovillous adenomas on routine colonoscopy.<sup>7</sup> Additionally, Soravia, et al., characterized

mutations located in exon 9 in two kindred with AFAP: one with deletion of nucleotide 'A' causing frameshift and early stop codon at nucleotide 1014 and the second with C to T substitution resulting in a nonsense mutation at nucleotide 994.<sup>8</sup> Therefore, the mutation found in our patient can be assumed to be associated with the AFAP.

The deleterious c.8297delC alteration in the *BRCA2* gene is a pathogenic mutation located in exon 17 of the *BRCA2* gene.<sup>9</sup> It causes a translational frameshift with a predicted alternate stop codon. The *BRCA2* protein is part of a complex that repairs homologous double-stranded breaks through the interaction with RAD51. Thus, *BRCA2*-deficient cells are unable to repair DNA damage and accumulate genetic alterations, often in genes important for cell cycle checkpoint. Cells with genetic alterations are able to continue with cell cycle and prog-



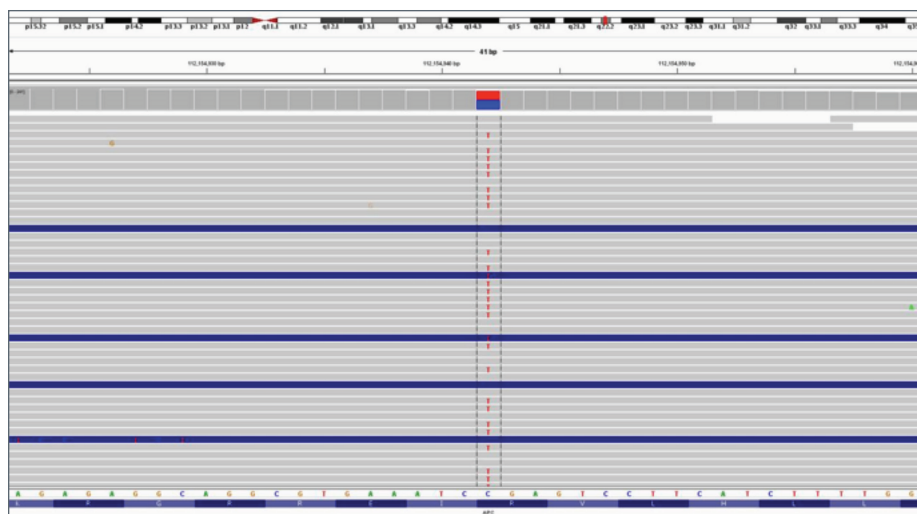


Fig. 1: Results from next-generation sequencing showing a substitution from C to T in the *APC* gene.

ress to neoplasia.<sup>10-12</sup> In females, while both *BRCA1* and *BRCA2* mutations are associated with cancer of breast, ovary, fallopian tubes, and peritoneum, *BRCA1* confers a greater risk. On the other hand, in males, *BRCA2* confers greater risk of breast, prostate, and pancreatic cancer. *BRCA* mutations have been associated with melanoma, gastric, and hematological malignancies. Currently, there are no well-established guidelines for managing male *BRCA2* patients.<sup>11,12</sup> It is recommended that the patient be counseled regarding risk of various malignancies and that surveillance be conducted of the various cancers as for a high-risk patient.<sup>12</sup>

**Conclusion:** To our knowledge this is the only reported case of coexistence of *APC* and *BRCA2* pathogenic mutation.

Based on the *KRAS* mutational status, our patient would not have benefited from anti-EGFR therapies and thus he was spared the expense and side effects associated with this therapy. Seven months after his initial presentation, his CEA rose and MRI revealed three new

liver lesions as well as recurrence at the site of anastomosis. He underwent total colectomy. Two liver lesions were biopsied and the third was ablated. The two biopsied lesions were negative for metastatic carcinoma. He was started on adjuvant 5-FU and bevacizumab (Avastin). The patient's liver lesion will be followed with serial CEA levels.

Although our patient did not have children, the germline mutation in the *APC* gene indicates the need for further evaluation of his sibling and the maternal side of the family. This should include genetic counseling and testing so that earlier and more frequent

endoscopic screenings can be performed as appropriate. The patient himself will be screened by esophagogastroduodenoscopy.

Because of the germline mutation in the *BRCA2* gene, the patient underwent mammogram. He will be surveyed for breast, skin, and prostate cancer. Based on the pedigree, it can be postulated that this germline mutation might be of paternal origin and may have played a role in the father's pancreatic cancer. We have encouraged the patient to discuss conformational testing of the *BRCA2* and *APC* mutations with his mother. □

1. Galiatsatos P, Foulkes WD. Familial adenomatous polyposis. *Am J Gastroenterol.* 2006;101(2):385-398.
2. Wilson PM, Labonte MJ, Lenz HJ. Molecular markers in the treatment of metastatic colorectal cancer. *Cancer J.* 2010; 16(3):262-272.
3. Weickhardt AJ, Price TJ, Chong G, et al. Dual targeting of the epidermal growth factor receptor using the combination of cetuximab and erlotinib: preclinical evaluation and results of the phase II DUX study in chemotherapy-refractory, advanced colorectal cancer. *J Clin Oncol.* 2012;30(13):1505-1512.

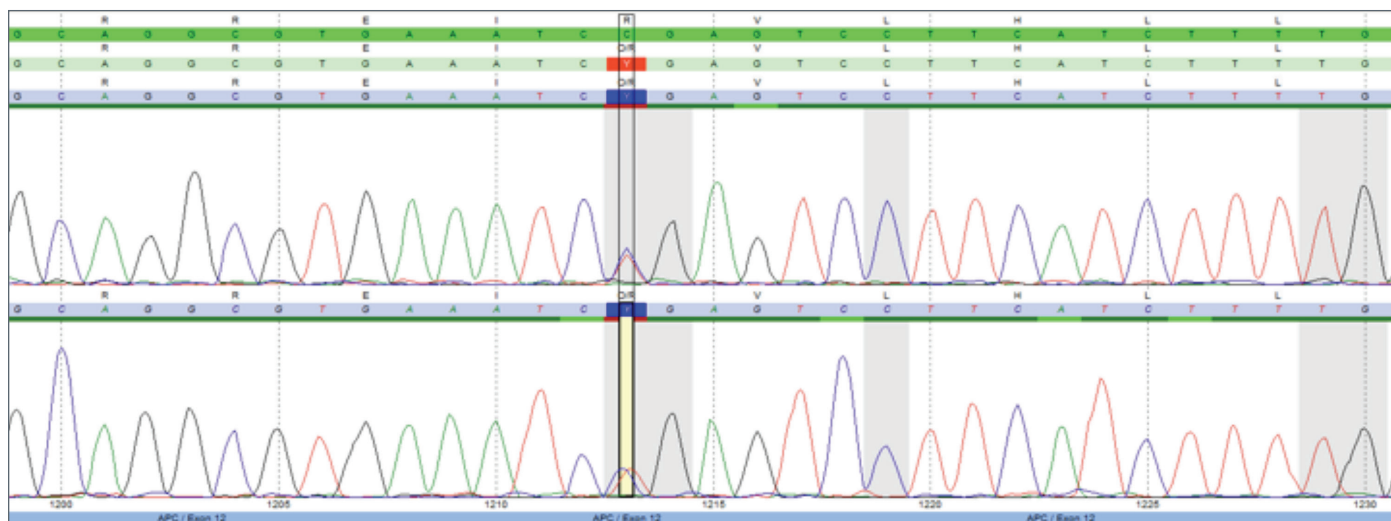


Fig. 2: Chromatogram of Sanger sequencing confirming the findings by next-generation sequencing.

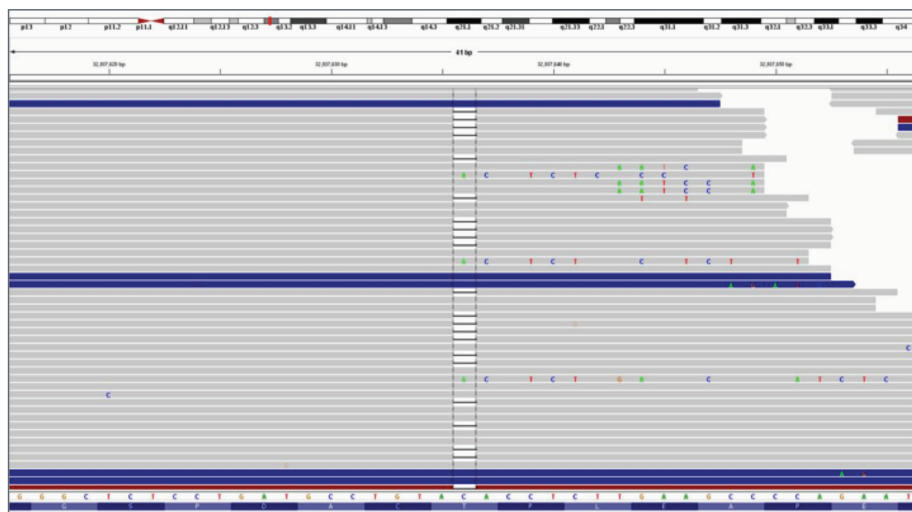


Fig. 3: Next-generation sequencing results showing deletion of C in the *BRCA2* gene. (See Fig. 4.)

4. Tol J, Punt CJ. Monoclonal antibodies in the treatment of metastatic colorectal cancer: a review. *Clin Ther.* 2010;32(3):437–453.

5. Peeters M, Douillard JY, Van Cutsem E, et al. Mutant *KRAS* codon 12 and 13 alleles in patients with metastatic colorectal cancer: assessment as prognostic and predictive biomarkers of response to panitumumab. *J Clin Oncol.* 2013;31(6):759–765.

6. Friedl W, Aretz S. Familial adenomatous polyposis: experience from a study of 1164 unrelated German polyposis patients. *Heredit Cancer Clin Pract.* 2005;3(3):95–114.

7. Gentner B, Kraus C, Schwab D, et al. A case of attenuated familial adenomatous polyposis coli (AFAP) [in German]. *Z Gastroenterol.* 2005;43(6):591–595.

8. Soravia C, Berk T, Madlensky L, et al. Genotype-phenotype correlations in attenuated adenomatous polyposis coli. *Am J Hum Genet.* 1998;62(6):1290–1301.

9. NM\_000059.3(*BRCA2*):c.8297delC (p.Thr2766Asnfs) AND Breast-ovarian

cancer, familial 2. <http://www.ncbi.nlm.nih.gov/clinvar/RCV000031732>.

10. Bougie O, Weberpals JL. Clinical considerations of *BRCA1*- and *BRCA2*-mutation carriers: a review. *Int J Surg Oncol.* 2011;2011. Article ID 374012: 11 pages.

11. Liede A, Karlan BY, Narod SA. Cancer risks for male carriers of germline mutations in *BRCA1* or *BRCA2*: a review of the literature. *J Clin Oncol.* 2004;22(4):735–742.

12. Mohamad HB, Apffelstaedt JP. Counseling for male *BRCA* mutation carriers: a review. *Breast.* 2008;17(5):441–450.

*Dr. Dolkar (PGY3 resident) and Dr. Siddiqui are in the Department of Pathology and Laboratory Medicine, Dr. Zikria is in the Department of Oncology, Dr. Bussell is in the Department of Surgery, and Morrill-Cornelius is a genetic counselor in the Hereditary Cancer Program—all at Danbury Hospital, Western Connecticut Health Network.*

**AMP** **CAP TODAY**  
 case report  
**Test yourself**

Here are three questions taken from the case report. Answers are online now at [www.amp.org/casereviews](http://www.amp.org/casereviews) and will be published next month in CAPTODAY.

**1.** Mutations in *KRAS* are associated with:

- a) resistance to EGFR tyrosine kinase inhibitors and monoclonal antibodies
- b) enhanced response to EGFR tyrosine kinase inhibitors and monoclonal antibodies
- c) no impact on response to EGFR tyrosine kinase inhibitors and monoclonal antibodies

**2.** Mutations in the *APC* gene result in:

- a) FAP
- b) AFAP
- c) Lynch syndrome
- d) a & b

**3.** Patients with AFAP phenotype have:

- a) alternatively spliced sequence in exon 9
- b) mutations in 5' to codon 168
- c) mutations in 3' to codon 1580
- d) all of the above

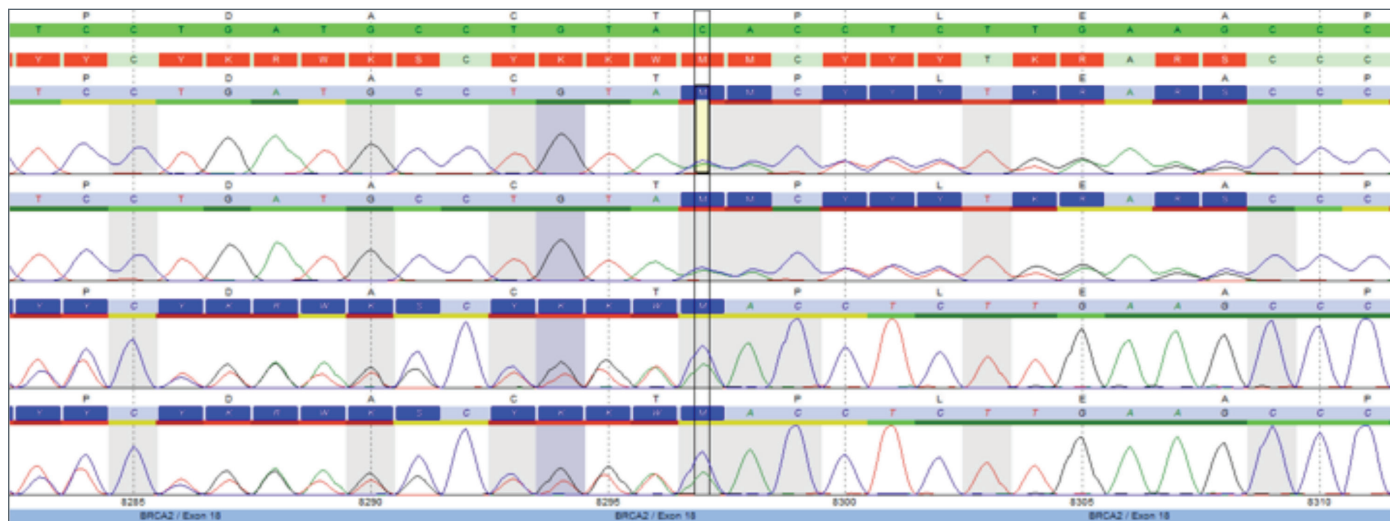


Fig. 4: Chromatogram of Sanger sequencing confirming the findings by next-generation sequencing. (See Fig. 3.)